



PATIENT

Peanut Grey

PRESENTING CLINICAL SIGNS

History: History chronic kidney disease. Progressive heart murmur, now grade III/VI systolic. BP: 140-150mmHg. *No sedation for study

SPECIES

Feline

ECHOCARDIOGRAM FINDINGS

2D, m-mode, color flow and Doppler imaging is available.

BREED

DSH

Left ventricle: The LV diameter is normal with adequate myocardial function. The LV is borderline in dimension without significant hypertrophy. There is a mildly hyperechoic endocardium consistent with fibrosis. The papillary muscles are mildly remodeled and mildly hypertrophied. The endocardium appears mildly remodeled.

SEX

Female Spayed

Left atrium: The left atrium is normal in dimension. No obvious spontaneous contrast or thrombi seen.

AGE

19 years

Mitral valve: The mitral valve is normal in structure. Mild systolic anterior motion is suspected. No obvious mitral regurgitation.

Aortic valve/Aorta: The aortic valve is normal in morphology and mobility. Mildly elevated aortic outflow velocity with turbulence noted on color flow. No aortic insufficiency.

WEIGHT

7.4lbs

Right ventricle: Normal right ventricular diameter and morphology indicating no overt evidence of pulmonary arterial hypertension.

Right atrium: The right atrium is normal in dimension.

Tricuspid valve: The tricuspid valve appears normal with no tricuspid regurgitation.

Pulmonic valve/Pulmonary artery: The pulmonic valve is normal in morphology and mobility. No pulmonic insufficiency.

Pericardium/other: No pericardial or pleural effusion noted. No obvious cardiac masses.

Heart rhythm: ECG reveals a sinus rhythm with an average HR of 190bpm.

INTERPRETED BY

Maggie Machen
Lamy, DVM
DACVIM (Cardiology)

2-Dimensional Measurements

| | |
|--------------------|------|
| Ao diam (cm) | 0.9 |
| LA diam (cm) | 1.2 |
| LA:Ao (Swe) | 1.3 |
| IVS thickness (cm) | 0.56 |
| LVID diastole (cm) | 1.2 |
| PW thickness (cm) | 0.60 |
| LVID systole (cm) | 0.51 |
| FS (%) | 54 |

Doppler Measurements

| | |
|----------------|-----|
| PV Vmax (m/s) | NM |
| AoV Vmax (m/s) | 2.8 |
| MR Vmax (m/s) | NA |
| TR Vmax (m/s) | NA |
| TR PG (mmHg) | NA |

IMAGING

PERFORMED BY

Jennifer Migner,
RDCS

HOSPITAL NAME

Firehouse Veterinary
Clinic

INTERPRETATION OF THE FINDINGS

Mild abnormalities are identified in this study. The LV walls measure borderline in dimension; however, no significant hypertrophy is seen. The murmur appears to be due to a mild dynamic LVOT obstruction likely secondary to tachycardia and volume depletion. These findings in combination may reflect early hypertrophic disease; however, there is no significant pathology noted at this time. The LA is normal indicating low risk for complications. No additional issues are identified.

REFERRING VET

Dr. Fleming

INVOICE

23089

Given these findings, the risk for complication is low. There is no indication for Atenolol therapy at this time in a senior cat. Follow up is advised. Prognosis is guarded until progression is assessed.

DATE

3/15/22



PATIENT

Peanut Grey

SPECIES

Feline

BREED

DSH

SEX

Female Spayed

AGE

19 years

WEIGHT

7.4lbs

INTERPRETED BY

Maggie Machen
 Lamy, DVM
 DACVIM (Cardiology)

IMAGING PERFORMED BY

Jennifer Migner,
 RDMS

HOSPITAL NAME

Firehouse Veterinary
 Clinic

REFERRING VET

Dr. Fleming

INVOICE

23089

DATE

3/15/22

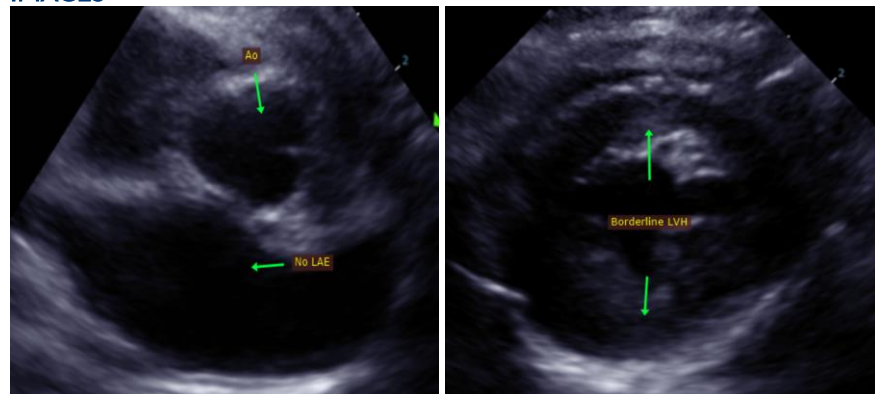
RECOMMENDATIONS

- Given these findings, no medications are indicated.
- Monitor BP and T4 every 6 months.
- Monitor for any clinical evidence of cardiac compromise, including respiratory changes and/or signs of a blood clot event (paralysis, neurologic changes, etc.).
- Anesthetic risk is considered mild, however judicious IV fluid rates are advised to avoid fluid overload. Additionally, drugs that stimulate heart rate should be avoided unless clinically necessary (glycopyrrolate, atropine). Avoid vasodilators as this may worsen the obstruction. A reasonable protocol includes opioid/benzodiazepine premedication, propofol induction, isoflurane maintenance. Additionally, steroids should be used with caution on older cats, as even a 'normal' geriatric heart can develop evidence of intolerance and fluid retention.

PLAN

- Recommend recheck echocardiogram in 6-12 months to screen for progressive LVH.

IMAGES



The information and recommendations provided are based on the images presented by the referring veterinarian. No evaluation can be communicated regarding pathology that was not visible in the image/video clips provided.

Thank you for this referral. This report was generated using transcription software, and minor dictation errors may be present. If the clinical or image interpretation does not parallel your findings or if I can be of any further assistance, please contact me.

Maggie Machen Lamy, DVM
 Diplomate of the American College of Veterinary Internal Medicine (Cardiology)
 info@sonopath.com